

12**AUTOPSY REPORT**

No. 2023-12242

MOONEY, MALEESA MARIE

I performed an autopsy on the body of →
 at the DEPARTMENT OF MEDICAL EXAMINER

Los Angeles, California on September 17, 2023 at 8:30 hours

(Date)

(Time)

From the anatomic findings and pertinent history I ascribe the death to:

(A) HOMICIDAL VIOLENCE

DUE TO OR AS A CONSEQUENCE OF
(B)DUE TO OR AS A CONSEQUENCE OF
(C)DUE TO OR AS A CONSEQUENCE OF
(D)

OTHER CONDITIONS CONTRIBUTING BUT NOT RELATED TO THE IMMEDIATE CAUSE OF DEATH

MANNER OF DEATH

HOMICIDE

HOW INJURY OCCURRED

INFLECTED BY OTHER(S)

Autopsy Summary :

- I. Blunt force trauma, head and neck:
 A. Triangular laceration (3/4 x 1/4 inch) above the left eyebrow
 B. Abrasions and contusions of the face and scalp
- II. Blunt force trauma, torso:
 A. Multiple linear abrasion/contusions across the back
- III. Blunt force trauma, extremities:
 A. Contusions of posterior left upper arm
 B. Abrasions of posterior left forearm
 C. Ligature furrow marks of bilateral wrists and ankles

CIRCUMSTANCES:

Please see Investigator's Report.

IDENTIFYING FEATURES:

The body is identified by toe tags and is that of an unembalmed, refrigerated, well-developed, well-nourished adult female who appears the reported age of 31 years. The body is approximately 65 inches and weighs 122 pounds. There are linear scars on the breasts bilaterally.

12**AUTOPSY REPORT**

No. 2023-12242

MOONEY, MALEESA MARIE

Page 2**DESCRIPTION OF BLUNT FORCE TRAUMATIC INJURIES:****Blunt force trauma, head and neck:**External:

1. Triangular laceration above the left eyebrow (3/4 x 1/4 inch)
2. Purple contusion above the right eyebrow (1/2 x 1/2 inch)
3. Abrasion on mid forehead (1/4 inch)
4. Periorbital ecchymosis of the right eye and extending to right cheek (3 x 3 inches)
5. Upper and lower right lip contusion/abrasions (1 x 1/4 inch each)

Internal:

1. Subcutaneous hemorrhages of the left and right frontal scalp (2 inches each in greatest dimension)
2. Subcutaneous hemorrhage of the occipital scalp slightly right of the posterior midline (1 x 1/2 inch)

Blunt force trauma, torso:External:

1. Multiple transverse linear red to purple contusion/abrasions across the upper back (2 x 1/4 inch each)
2. Erythematous discoloration of the skin overlying the anterior superior iliac spines of the pelvis (anterior hips)

Internal:

1. Fracture of left rib number 11 on the anterolateral aspect without hemorrhage.

Blunt force trauma, extremities:External:

1. Transverse linear contusions of the posterior upper left arm (2-1/2 x 1/4 inch each)
2. Left posterior forearm: three small abrasions measuring (1/4, 1/2, and 1/4 inch each)
3. Ligature furrows of bilateral wrists and ankles with no definitive traumatic vital reaction identified

12**AUTOPSY REPORT**

No. 2023-12242

MOONEY, MALEESA MARIE

Page 3

Note: The following observations are limited to findings other than the injuries described above.

EXTERNAL EXAMINATION:

The scalp is covered by black hair with hair extensions. Examination of the eyes reveals brown irides and white sclera. The conjunctivae are congested. No definitive petechial hemorrhages of the sclerae, conjunctivae, or oral mucosae are identified. The oronasal passages are unobstructed. There is no foam or foreign material in the nares or oral cavity. Upper and lower teeth are present and in good repair. No petechial hemorrhages of the gingival or oral mucosa are identified. The upper and lower frenulae are intact. There is faint, band like, erythematous discoloration across the anterior neck.

There is no chest deformity. There is no increased anterior-posterior diameter. There are bilateral breast implants with surgical scars. On the anterior left chest, lateral to midline, there is a crescent shaped area of faint erythematous discoloration (4 x 2 inches). The abdomen is flat and otherwise unremarkable. The genitalia are those of an adult female. The external genitalia are unremarkable.

On the anterior left shoulder there is a yellow-orange abrasion measuring 2 x 1 inches. On the superior posterior left shoulder there is a yellow-orange abrasion measuring 1 x 1 inch. There is focal area of abrasion/skin slip on the posterior left wrist measuring 1/4 inch in greatest dimension.

EVIDENCE OF THERAPEUTIC INTERVENTION:

The following findings include only those present at the time of autopsy and do not include medical therapeutic devices removed prior to autopsy. There is no evidence of recent therapeutic intervention. Recent needle punctures are not identified. There has not been postmortem intervention for tissue/organ procurement.

POSTMORTEM CHANGES:

Rigor mortis is partially present. Livor mortis is faint, predominately posterior, and fixed.

12**AUTOPSY REPORT**

No. 2023-12242

MOONEY, MALEESA MARIE

Page 4**INITIAL INCISION:**

The body cavities are entered through the standard coronal scalp incision and the standard Y-shaped chest and abdomen incision.

INTERNAL EXAMINATION:**NECK:**

Following a layered anterior neck dissection the neck organs are removed en bloc with the tongue. There is no edema of the larynx. Both hyoid bone and larynx are intact and without fractures or hemorrhage. No hemorrhage is present in the adjacent throat organs, investing fascia, strap muscles, thyroid, or visceral fascia. There are no prevertebral fascial hemorrhages. The tongue when sectioned shows no trauma.

BODY CAVITIES:

The chest and abdominal cavities have no hemorrhage or abnormal fluid. The serosal surfaces are smooth, glistening, and without adhesions. The organs are normally located. The diaphragm is intact.

SYSTEMIC AND ORGAN REVIEW:**MUSCULOSKELETAL SYSTEM:**

No abnormalities of the examined bony framework or muscles are identified.

CARDIOVASCULAR SYSTEM:

The pericardium is thin and smooth and the pericardial sac is unremarkable without blood or excessive fluid.

The heart weighs 200 grams and has a normal configuration. The cardiac shape is not globular and the myocardium is not flabby. The chambers are normally developed and are without mural thrombosis. The myocardium is red-brown and uniform without gross fibrosis or areas of discoloration. The right ventricle, interventricular septum and left ventricle measure 0.3 cm, 0.9 cm, and 1.0 cm in thickness, respectively.

The endocardium is smooth and glistening without discoloration. There are no defects of the septum. The cardiac valves contain the anatomically normal number of leaflets, which are thin, pliable, leafy, and appear competent. No cardiac valve

12**AUTOPSY REPORT**

No. 2023-12242

MOONEY, MALEESA MARIE

Page 5

vegetations are present. The tricuspid, pulmonic, mitral and aortic valve measure 12 cm, 7.5 cm, 11 cm, and 7.5 cm respectively. There is no abnormality of the apices of the papillary musculature.

The great vessels enter and leave the heart in a normal fashion. The coronary ostia are patent, located at or below the sinotubular junction, and are relatively centrally located within their respective sinuses. The coronary artery distribution is right dominant. Serial sectioning of the coronary arteries shows no significant atherosclerotic stenosis.

The thoracic and abdominal aorta have minimal atherosclerosis. There is no tortuosity or widening of the thoracic segment. There is no dilation of the lower abdominal segment. No aneurysm is present. The major branches of the aorta show no abnormality.

RESPIRATORY SYSTEM:

Scant secretions are found in the upper respiratory and lower bronchial passages. There is no foreign material within the upper airways or trachea. The right and left lungs weigh 325 grams and 250 grams, respectively. The pulmonary parenchyma is dark red-purple and the cut surfaces exude a scant amount of blood and fluid. The visceral pleurae are smooth and intact. The lungs have no consolidation, hemorrhage, mass lesions, or gross enlargement of airspaces. The pulmonary vasculature is without thromboembolism.

GASTROINTESTINAL SYSTEM:

The esophagus is intact throughout and without ulcers or varices. The stomach contains brown fluid without identifiable food particles or pill tablets. The mucosa is unremarkable. The small intestine and colon are unremarkable. The appendix is present and unremarkable. The pancreas occupies a normal position and is brown-tan, lobulated and without necrosis, fibrosis, or hemorrhage.

HEPATOBIILIARY SYSTEM:

The liver weighs 1850 grams and is red-brown. Cut surfaces are uniform and smooth without masses, hemorrhage, or palpable

12**AUTOPSY REPORT**

No. 2023-12242

MOONEY, MALEESA MARIE

Page 6

fibrosis. The gallbladder has a thin and pliable wall and contains a moderate amount of bile with no calculi.

URINARY SYSTEM:

The right kidney weighs 100 grams and the left kidney weighs 125 grams. The kidneys are normally situated and the capsules strip easily revealing a surface that is smooth and glistening. The corticomedullary demarcation is preserved. The pyramids are not remarkable. The ureters appear unremarkable. The urinary bladder is unremarkable. It contains no urine.

GENITAL SYSTEM:

The uterus is symmetrical and the uterine cavity is not enlarged. The fallopian tubes are unremarkable. The endometrium is unremarkable. The cervix and vagina have a normal appearance for age. The ovaries are unremarkable.

HEMOLYMPHATIC SYSTEM:

The spleen weighs 75 grams. The capsule is intact. The parenchyma is dark red and soft. There is no increased follicular pattern.

The bone marrow of the ribs is unremarkable.

ENDOCRINE SYSTEM:

The thyroid, adrenal, and pituitary glands are unremarkable. The parathyroid glands are not individually dissected. The thymus is not well appreciated.

SPECIAL SENSES:

The eyes are not dissected. The middle and inner ear are not dissected.

HEAD AND CENTRAL NERVOUS SYSTEM:

The dura mater is stripped showing no fractures of the calvarium or base of the skull. There are no tears of the dura mater. There is no epidural, subdural or subarachnoid hemorrhage.

The brain weighs 1225 grams. The leptomeninges are thin and transparent. A normal convolutionary pattern is observed. Coronal sectioning demonstrates a uniformity of cortical gray thickness. The basal ganglia are intact. Anatomic landmarks

12**AUTOPSY REPORT**

No. 2023-12242

MOONEY, MALEESA MARIE

Page 7

are preserved. Cerebral contusions are not grossly identified. The ventricular system has a normal appearance without dilation or distortion. Pons, medulla, and cerebellum are unremarkable. Vessels at the base of the brain have a normal pattern of distribution. There are no aneurysms. The cerebral arteries do not show significant atherosclerosis.

SPINAL CORD:

The entire cord is not dissected. The superior portion of the cervical cord is examined through the foramen magnum and is unremarkable.

EVIDENCE COLLECTION:

No evidence is collected at the time of autopsy.

RETAINED TISSUE:

Representative sections from various organs are preserved in one storage jar.

HISTOLOGIC KEY:

1. Heart
2. Right lung
3. Left lung

TOXICOLOGY:

Heart blood is collected in an EDTA purple top tube and submitted to the lab as a typing specimen. Heart blood, femoral blood, liver tissue, and vitreous humor are collected and submitted to the lab. A toxicology screen is requested.

SPECIAL PROCEDURES:

A layered anterior neck dissection revealed no hemorrhage or other abnormal findings.

A layered posterior neck dissection revealed no hemorrhages or other abnormal findings.

Superficial dissection with subcutaneous exploration of the wrists and ankles revealed no hemorrhage associated with the ligature marks.

12**AUTOPSY REPORT**

No. 2023-12242

MOONEY, MALEESA MARIE

Page 8

Layered soft tissue dissection of the posterior torso revealed superficial hemorrhage associated with the linear contusion/abrasions observed externally but no deep soft tissue hemorrhages.

PHOTOGRAPHY:

Photographs have been taken prior to and during the course of the autopsy.

RADIOLOGY:

A postmortem computed tomography scan was performed. No retained foreign bodies or skeletal trauma are identified.

WITNESSES:

Detective A. Pierce of the Los Angeles Police Department was present to witness and discuss the findings at the time of autopsy.

DIAGRAMS USED:

Diagram forms #20 and 22 was used during the performance of the autopsy. Medical examiner diagrams are not intended to be facsimiles nor are they drawn to scale.

SUMMARY & OPINION:

This 31 year-old woman, Maleesa Marie Mooney, was last seen alive on surveillance video at her apartment complex on the afternoon of 09/06/2023. On 09/12/2023, the decedent's mother called requesting a welfare check. Law enforcement officers responded and entered the secured apartment using the property management's key. They found Ms. Mooney's body wedged inside the refrigerator with pooled blood beneath it. Her wrists were bound together, her ankles were bound together, and these bindings were tied to each other behind her back with miscellaneous electronic cords and clothing items. Additional clothing items were around her face and neck. An apparent gag, fashioned out of an article of clothing, was stuffed in her mouth.

Autopsy revealed blunt force injuries of the face/head, back, and upper left arm. Examination of the wrists and ankles where the ligature bindings were tied showed no vital reaction to indicate that they were applied antemortem. No anatomic evidence of significant natural disease was identified.

12**AUTOPSY REPORT**

No. 2023-12242


MOONEY, MALEESA MARIE

Page 9

Toxicological testing of postmortem specimens detected the presence of benzoylecgonine, cocaethylene, and ethanol (up to 0.063 g%) in Ms. Mooney's system. Benzoylecgonine is a cocaine metabolite, and its' presence indicates recent cocaine use. Cocaethylene is formed in the body when cocaine and ethanol are present simultaneously.


The blunt force traumatic injuries observed at autopsy are generally not considered acutely life threatening on their own. However, based on the circumstances of how Ms. Mooney was found, these injuries suggest she was likely involved in violent physical altercation prior to her death. Given this, the role that drugs and/or alcohol may have played in Ms. Mooney's death, if any, is uncertain.

Based on the history, circumstances, and autopsy findings, as currently known, Ms. Mooney's death was likely the result of, or at least related to, the actions of another individual(s). In particular, there is suspicion for homicidal asphyxia in this case. Characteristic anatomic findings of strangulation were not appreciated at autopsy, but the lack of these findings cannot exclude homicidal asphyxia by other mechanisms. Without findings to elucidate a clear mechanism of death, or knowledge of the sequence of events leading to Ms. Mooney's death, the cause of death is deemed homicidal violence. The manner of death is homicide.



Sami Souccar, MD
Associate Medical Examiner

10/18/23
Date

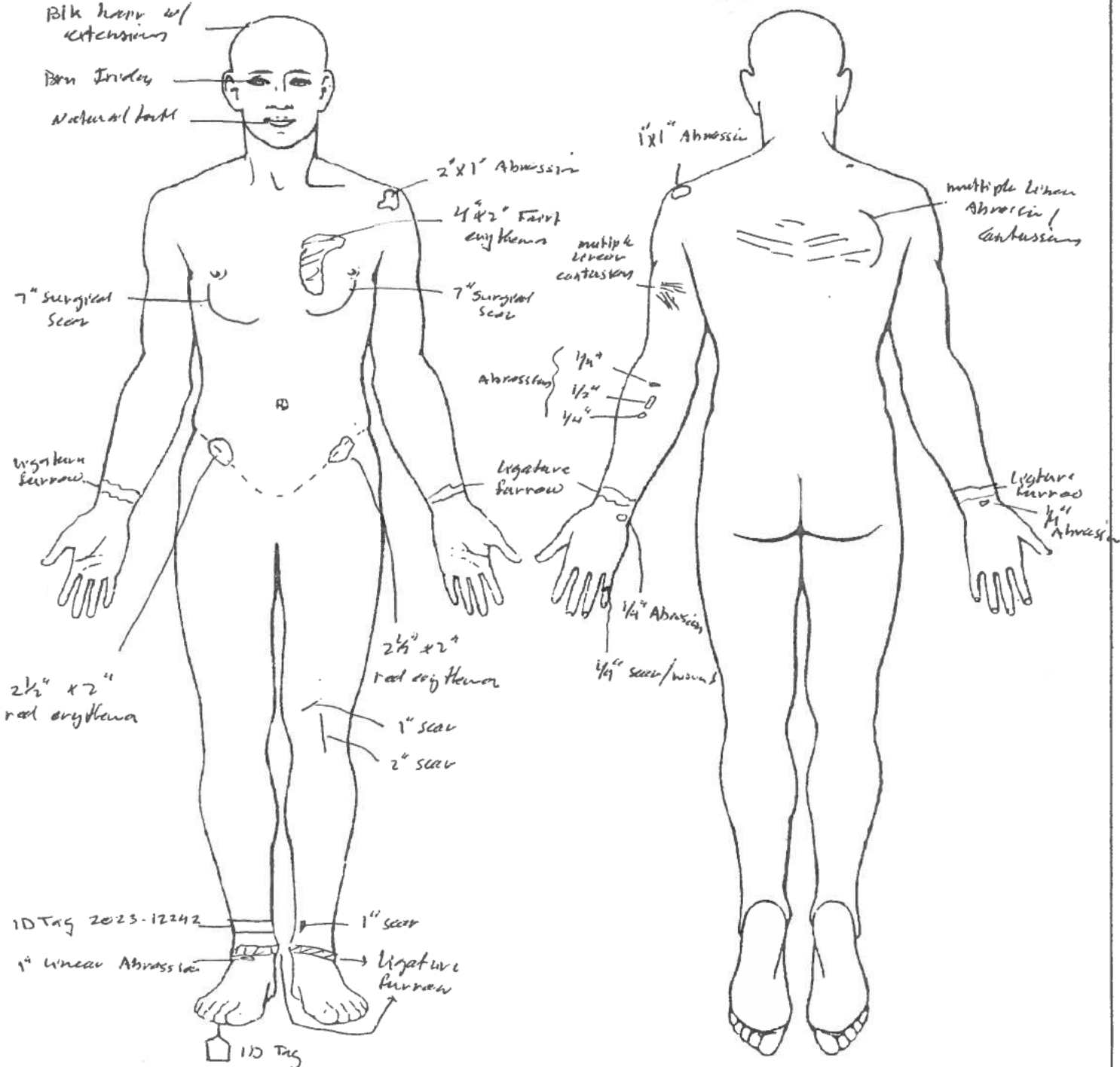


Brice Hunt, M.D.
Interim Senior Deputy Medical Examiner


10-18-2023
Date

20

2023-12242
MOONEY, MALEESA
HOMI 342



Date 09/17/23


 Deputy Medical Examiner M.D.

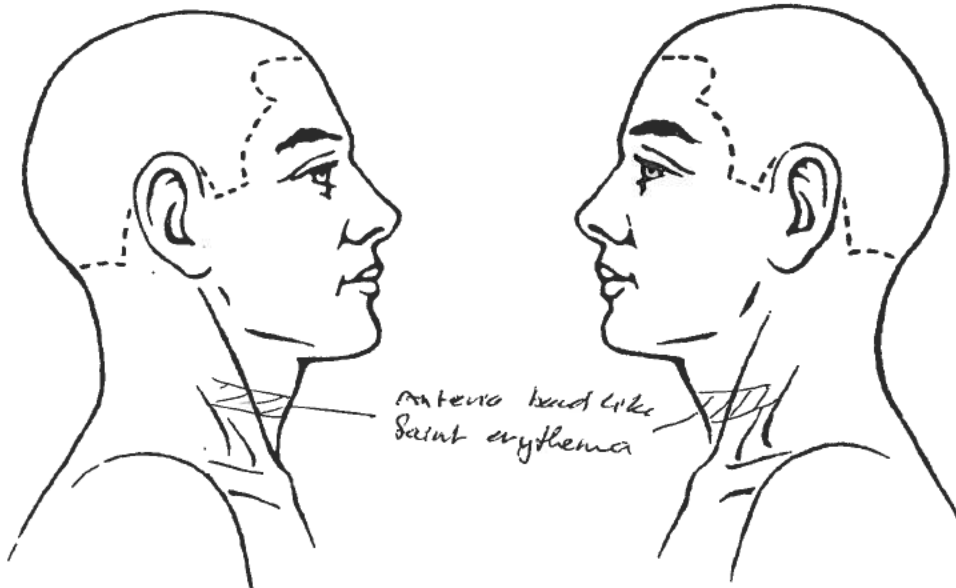
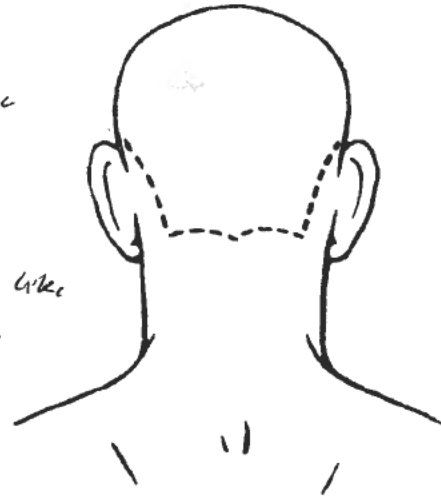
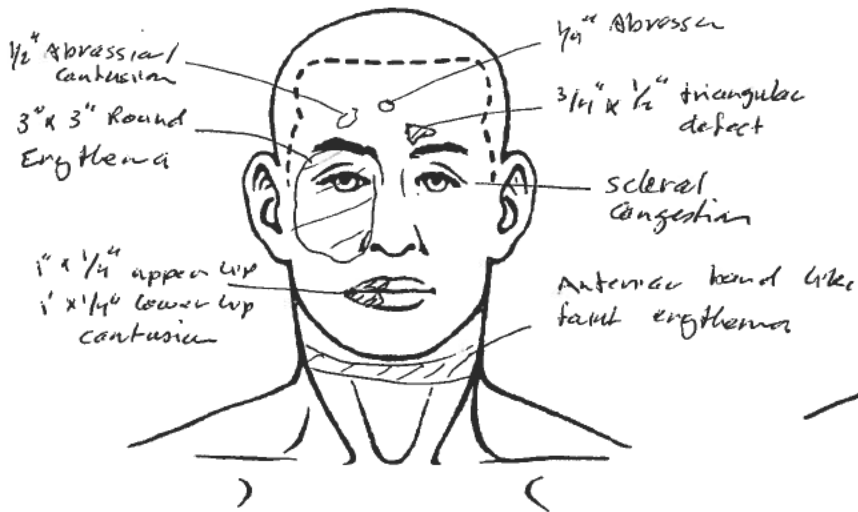
22

2023-12242

MOONEY, MALEESA

HOMI

342



Date 09/17/23

[Signature] 73746

M.D.

Deputy Medical Examiner

16

2023-12242

HOONEY, HALEESA

HOMI

342

EXTERNAL EXAM

Sex
 Race
 Age
 Height
 Weight
 Hair
 Eyes
 Sclera
 Teeth
 Mouth
 Tongue
 Nose
 Chest
 Breasts
 Abdomen
 Scar
 Genitals
 Edema
 Skin
 Decubitus
HEART Wt. 200
 Pericardium
 Hypertrophy
 Dilation
 Muscle
 Valves
 Coronaries
AORTA
VESSELS
LUNGS Wt.
 R 325
 L 250
 Adhesions
 Fluid
 Atelectasis
 Oedema
 Congestion
 Consolidation
 Bronchi
 Nodes
PHARYNX
TRACHEA
THYROID
THYMUS
LARYNX
HYOID
ABDOMINAL WALL FAT < 1/4"

RV 0.3
 Septum 0.9
 LV 1.0
 Septum

PERITONEUM

Fluid
 Adhesions
LIVER Wt. 1850
 Capsule
 Lobules
 Fibros
 G BGD
 Calculus
 Bile ducts
SPLEEN Wt. 75
 Color
 Consistency
 Capsule
 Malpiment
PANCREAS
ADRENALS
KIDNEYS Wt.
 R 100
 L 125
 Capsule
 Cortex
 Vessels
 Pelvis
 Ureters
BLADDER *φ carcinoma*
GENITALIA
 Prostate
 Testes
 Uterus
 Tubes
 Ovaries
OESOPHAGUS
STOMACH
 Contents *Brown liquid*
DUOD. & SM. INT.
APPENDIX
LARGE INT.
ABDOM. NODES
SKELETON
 Spine
 Marrow
 Rib Cage
 Long bones
 Pelvis

SCALP

CALVARIUM
BRAIN Wt. 1225
 Dura
 Fluid
 Ventricles
 Vessels
 Middle ears
 Other
PITUITARY *φ*

SPINAL CORD

TOXICOLOGY SPECIMENS

SECTIONS FOR HISTOPATHOLOGY

1 - Heart
 2 - R lung
 3 - L lung

MICROBIOLOGY

DIAGRAMS
X-RAYS

OTHER PROCEDURES

GROSS IMPRESSIONS

Date 9/17/23

Time
 Start 9:30
 end 11:45

Deputy Medical Examiner

14**MICROSCOPIC REPORT**

Date slides examined: September 27, 2023
County of Los Angeles Department of Medical Examiner-Coroner
Los Angeles, California

No. 2023-12242

MOONEY, MALEESA MARIE

Diagnoses:**1. HEART:**

- Mild myocyte enlargement.

2. LUNG:

Vascular congestion and edema.


Microscopic description:

Heart sections: Scattered enlarged myocyte nuclei with squared edges. No myocardial fibrosis is identified. No intracytoplasmic inclusions are not identified. The endocardium is unremarkable. No inflammatory infiltrates are identified. There are no regions of hemorrhage or necrosis.

Lung section: Vascular congestions and edema without acute inflammatory infiltrates There is no inflammation of the bronchioles. No inflammation or hyaline membranes are seen within the alveoli.


Slide Key:

1. Heart.
2. Left ventricle.
3. Right ventricle



Sami Souccar, MD
Associate Medical Examiner

9/27/23
Date



Brice Hunt, M.D.
Interim Senior Deputy Medical Examiner

9-27-2023
Date



Department of Medical Examiner, County of Los Angeles
FORENSIC SCIENCE LABORATORIES

1104 North Mission Road, Los Angeles, CA 90033

Laboratory Analysis Summary Report



Hunt, Brice M.D.

Deputy Medical Examiner
 1104 North Mission Road
 Los Angeles, CA 90033

PendingTox

Case Number: 2023-12242

Decedent: MOONEY, MALEESA MARIE

| <u>SPECIMEN</u> | <u>SERVICE</u> | <u>DRUG</u> | <u>RESULT</u> | <u>ANALYST</u> |
|--|-------------------|--------------------------------------|---------------|----------------|
| Alcohol Quantitation/Confirmation | | | | |
| Blood, Femoral | | | | |
| | Alcohol-GC/FID-HS | Ethanol | 0.052 g% | C. Castellino |
| Blood, Heart | | | | |
| | Alcohol-GC/FID-HS | Ethanol | 0.043 g% | C. Castellino |
| Vitreous | | | | |
| | Alcohol-GC/FID-HS | Ethanol | 0.063 g% | C. Castellino |
| Drug Screen | | | | |
| Blood, Heart | | | | |
| | ELISA-Immunoassay | Cocaine and Metabolites | PP | J. Posada |
| | ELISA-Immunoassay | Fentanyl | ND | J. Posada |
| | ELISA-Immunoassay | Methamphetamine & MDMA | ND | J. Posada |
| | ELISA-Immunoassay | Opiates: Codeine & Morphine | ND | J. Posada |
| | ELISA-Immunoassay | Opiates: Hydrocodone & Hydromorphone | ND | J. Posada |
| | ELISA-Immunoassay | Phencyclidine | ND | J. Posada |
| Drug Screen/Confirmation | | | | |
| Blood, Femoral | | | | |
| | Cocaine-GC/MS | Benzoylcegonine | 0.25 ug/mL | J. Fallot |
| | Cocaine-GC/MS | Cocaethylene | *<0.025 ug/mL | J. Fallot |
| | Cocaine-GC/MS | Cocaine | ND | J. Fallot |
| Blood, Heart | | | | |
| | Cocaine-GC/MS | Benzoylcegonine | 0.24 ug/mL | J. Fallot |
| | Cocaine-GC/MS | Cocaethylene | ND | J. Fallot |
| | Cocaine-GC/MS | Cocaine | ND | J. Fallot |

Case Number: 2023-12242

Decedent: MOONEY, MALEESA MARIE

SPECIMEN SERVICE DRUG RESULT ANALYST

NOTE: *Result is less than the quantification limit.

| | | | | | |
|----------------|--------------|-------|--------------------------|-------|---------------------------|
| Legend: | | ND | Not Detected | SNS | Specimen Not Suitable |
| g | Grams | ng/g | Nanograms per Gram | TNP | Test Not Performed |
| g% | Gram Percent | ng/mL | Nanograms per Milliliter | ug | Micrograms |
| Inc. | Inconclusive | PP | Presumptive Positive | ug/g | Micrograms per Gram |
| mg | Milligrams | QNS | Quantity Not Sufficient | ug/mL | Micrograms per Milliliter |

The alcohol analysis was performed in accordance to California Code of Regulations "Title 17" compliance by a qualified analyst in the Forensic Toxicology Laboratory, Forensic Laboratories Division, County of Los Angeles Department of Medical Examiner.

Enzyme-linked immunosorbant assay (ELISA) provides only a preliminary analytical result that is contingent upon a confirmatory test. A "presumptive positive" (PP) signifies a detection of a drug class and must be confirmed by additional testing for true identification and/or quantitation of specific drug(s) present in the specimen.

Per the Department's Evidence Retention Policy, the blood specimen(s) will be retained for one year (minimum) and all other specimens six months (minimum) from Postmortem Exam.

Final Review By: Sarah Buxton
Digitally signed by Sarah Buxton de Quintana
Date: 2023.10.03 11:06:13 -07'00'
Sarah Buxton de Quintana
Supervising Criminalist I

The above results relate only to the items sampled and tested and have been technically and administratively reviewed and are the opinions and conclusions of the analysts noted. The final review has been certified by the noted Toxicologist to ensure that all standard operating procedures were followed as set by the Forensic Toxicology Laboratory, Forensic Sciences Laboratory Division, County of Los Angeles Department of Medical Examiner.



LOS ANGELES COUNTY Medical Examiner

Case Number: **2023-12242** - Decedent's Name: **MOONEY, MALEESA MARIE**

| | | | | | | | | | | | |
|---|-----------------------|-------------------------------------|---------------|---|---|--|------------|--------------------|---------------------|----------|-----------|
| COUNTY OF LOS ANGELES | | INVESTIGATIVE SUMMARY REPORT | | | | DEPARTMENT OF MEDICAL EXAMINER | | | | | |
| 1 | APPARENT MODE | | Homicide | | | | CASE NO | | | | |
| | SPECIAL CIRCUMSTANCES | | | | | | 2023-12242 | | | | |
| | | Victim of Crime | | | | CRYPT G-342 | | | | | |
| LAST, FIRST MIDDLE | | | | | | AKA | | # | | | |
| MOONEY, MALEESA MARIE | | | | | | | | | | | |
| ADDRESS | | | | | | CITY | | STATE | | ZIP | |
| 222 South Figueroa Street #520, Los Angeles, California 90012 | | | | | | | | | | | |
| County Los Angeles | | | | | | | | | | | |
| SEX | RACE APPEARS | DOB | AGE | HGT | WGT | EYES | HAIR | TEETH | FACIAL HAIR | ID VIEW | CONDITION |
| Female | Black | 10/16/1991 | 31 y | | 122 lb | Brown | Brown | Natural | No | Yes | FAIR |
| MARK TYPE | | | MARK LOCATION | | | MARK DESCRIPTION | | | | | |
| Scar | | | Both Breasts | | | Old, healed-Around both nipples, vertical down the lower central portion, and curved underneath. Front-Old, healed approximately 3" | | | | | |
| Scar | | | Left Knee | | | | | | | | |
| NOK | | | ADDRESS | | | CITY | | STATE | | ZIP | |
| Mother | | | PHONE | | | PENDING BY | | DATE | | TIME | |
| SSN | | | DL ID | | | STATE | | | | | |
| | | | | | | CALIFORNIA | | | | | |
| ID METHOD | | | | | | | | | | | |
| Fingerprints-Livescan | | | | | | | | | | | |
| L.A. # | | MAIN # | | CIL # | | FBI # | | MILITARY # | | POB | |
| | | | | | | | | | | | |
| IDENTIFIED BY NAME(PRINT) | | | | RELATIONSHIP | | PHONE | | DATE | | TIME | |
| | | | | | | | | 9/13/2023 | | 08:19:00 | |
| PLACE OF DEATH/PLACE FOUND | | | | ADDRESS OR LOCATION | | | | CITY | | ZIP | |
| Residence | | | | 222 South Figueroa Street #520, Los Angeles, California 90012 | | | | County Los Angeles | | | |
| PLACE OF INJURY | | AT WORK | DATE | TIME | LOCATION OR ADDRESS | | | | ZIP | | |
| Residence | | No | | | 222 South Figueroa Street #520, Los Angeles, California 90012 | | | | County Los Angeles, | | |
| DOD | | TIME | | FOUND OR PRONOUNCED BY | | | | | | | |
| 9/12/2023 | | 16:25:00 | | Artiaga, Sergeant | | | | | | | |
| OTHER AGENCY INV OFFICER | | | | PHONE | | | | REPORT No | | | |
| LAPD CENTRAL BUREAU HOMICIDE | | | | 213-486-8700 | | | | | | | |
| TRANSPORTED BY | | | | DATE | | | | TIME | | | |
| Aque, Tami | | | | 9/13/2023 | | | | 04:18:00 | | | |
| FINGERPRINTS? Yes | | CLOTHING No | | | PARPT No | | | MORTUARY | | | |
| | | | | | | | | | | | |
| MED EV No | | INVEST PHOTOS# 280 | | | SEAL TYPE NOT SEALED | | | HOSP RPT No | | | |
| | | | | | | | | | | | |
| PHYS EV Yes | | | | | PROPERTY? No | | | HOSP CHART No | | | |
| | | | | | | | | | | | |
| SUICIDE NOTE No | | | | | | | | PF NO | | | |
| | | | | | | | | | | | |



LOS ANGELES COUNTY Medical Examiner

Case Number: **2023-12242** - Decedent's Name: **MOONEY, MALEESA MARIE**

SYNOPSIS

According to the reported information, the decedent is a 31-year-old black female. The decedent was last seen alive on surveillance video at her apartment complex on Wednesday 09/06/2023 at an unknown time in the afternoon. On Thursday 09/07/2023, an unknown male is seen on surveillance video using the decedent's key FOB to use the elevator. On Sunday 09/10/2023, the decedent's sister called the Los Angeles Police Department-Central requesting a welfare check. Officers arrived at the decedent's apartment and knocked on the front door, and there was no answer. There was no signs of nefarious activity, so entry was not made. On Tuesday 09/12/2023, the decedent's mother called requesting a welfare check, and Officers from the Los Angeles Police Department-Central responded, and entered the locked and secured apartment using the managements key. They observed food that belonged in the refrigerator on the kitchen counter. When they opened the refrigerator, they found the decedent inside, unresponsive. On Tuesday 09/12/2023 at 1625 hours, Sergeant Artiaga determined death. The suspect(s) is not in custody. It is unknown about the weapon(s). Both Detective Marsinek and Detective Pierce require a 2-hour notification prior to the examination. Please see case notes for their contact information.



LOS ANGELES COUNTY Medical Examiner

Case Number: 2023-12242 - Decedent's Name: MOONEY, MALEESA MARIE

COUNTY OF LOS ANGELES

Investigator's Narrative

DEPARTMENT OF CORONER

Information Sources:

- (1) Los Angeles Police Department-Central Bureau Homicide (213)486-8700
Detective Marsinek

Investigation:

On Tuesday 09/12/2023 at 1922 hours, Detective Gibson from the Los Angeles Police Department-Central Bureau Homicide made a first call to the Los Angeles Medical Examiner's Office to report a homicidal death of a black female. On Wednesday 09/13/2023 at 0215 hours, Lieutenant Kelly Yagerlener assigned this case to me. I arrived on-scene at 0240 hours, and I cleared the scene at 0400 hours. Forensic Attendant Tami Aque transported the decedent from the scene to the Decedent Services Unit. Criminalist Samantha Ingalls accompanied me to the scene, and collected all of the evidence regarding this case. Please see her supplemental report for further information. There are no suspect(s) in custody.

Location:

Location of Death: 222 South Figueroa Street #520, Los Angeles, California 90012 County Los Angeles Location of Injury: 222 South Figueroa Street #520, Los Angeles, California 90012 County Los Angeles

Informant/Witness Statements:

I spoke with Detective Marsinek at the scene, and he told me the following:

The decedent lives in this residence by herself, and she moved in in the beginning of 08/2023. Per surveillance video, on Tuesday 09/05/2023, the decedent, another female, and a male were seen getting into one of the elevators, go up to the 5th floor, and then exit. Per surveillance video, the decedent was last seen alive on Wednesday 09/06/2023 on one of the elevators, and her vehicle also was issued a parking ticket. Per surveillance video, on Thursday 09/07/2023, a male was seen using the decedent's key FOB to use the elevator, and then carrying plastic bags to the decedent's residence. On Saturday 09/09/2023, the decedent was supposed to go to her old residence to pick-up the rest of her belongings, but she never arrived. On Sunday 09/10/2023, the decedent's sister contacted the Los Angeles Police Department requesting a welfare check. Officers arrived on-scene, and knocked on the decedent's front door. There was no answer, and no entry was made. On Tuesday 09/12/2023, the decedent's mother called the manager of the apartment building requesting another welfare check. The manager then called the Los Angeles Police Department and Officers arrived on-scene. The manager opened the locked door with their key, and Officers entered the apartment. They looked around and did not locate the decedent. They then observed food that is usually kept in the refrigerator on the kitchen counters. They looked inside the refrigerator, and found the decedent, unresponsive. On Tuesday 09/12/2023 at 1625 hours, Sergeant Artiaga determined death. There are no suspect(s) in custody.

Scene Description:

A multiple story residential building was located at 222 South Figueroa Street in Los Angeles. Residence #520 was located on the 5th floor, in the west central portion of the residential building. The kitchen was located in the northeast portion of the residence. Located along the north wall was a counter with sink with cupboards above, and cupboards, drawers, and a dishwasher below. Located along the east wall, northeast portion was an oven and stove with a microwave and cupboards above. Located along the east wall, central portion was a counter with cupboards above and cupboards and drawers below. Located along the east wall, southeast portion was a refrigerator with cupboards above. The south side opened into the entry way and the family room. Located along the west wall was a bar with a trash can just east of it. The decedent was located lying inside the refrigerator. There was blood underneath the decedent, and on the bottom of the refrigerator.



LOS ANGELES COUNTY

Medical Examiner

Case Number: 2023-12242 - Decedent's Name: MOONEY, MALEESA MARIE

Body Examination:

The decedent is a 31-year-old black female with sparse black hair underneath the wig, and brown eyes. She has all of her upper and all of her lower natural teeth. There are old healed circular scars around both of her nipples. There are old healed vertical scars, down the lower central portion of her breasts. There are old healed curved scars underneath both of her breasts. There is an old healed vertical scar, approximately 3" in length down the front of her left knee. No other scars and no tattoos were noted. The decedent was wearing a leopard print romper, and a pair of blue underwear. There was a pink sweatshirt partially covering her head, and there was an animal print dress around both of her lower thighs. The decedent was located inside the refrigerator. The top of her head was facing east. Her right arm was bent at the elbow, and I was unable to see her left arm. Both of her legs were bent at the knees, with both of her feet in the southeast corner of the refrigerator, and were pointing east. Both of her wrists were tied together with multiple items, and then tied to both of her ankles. Wrapped partially around her face was a pink dress. Wrapped once around her neck was a gray dress, 3 rags, a gold piece of clothing, and a pink vest. Part of the pink vest was stuffed inside her mouth. Wrapped loosely around her lower forearms was a pink piece of clothing. Wrapped around her ankles and with some of the clothing around her head and neck was a yellow bikini top. Wrapped around her wrists and ankles were white phone charging cords, white shoelaces, and a black tank top. The black tank top and a tan tank top were also partially wrapped around her right ankle. The black tank top was in between the decedent's 2 hands. There were abrasions to the central portion of her forehead, and there was a large bump to the central portion of her forehead. There was a laceration above her left eyebrow, and there was apparent bruising with swelling to both of her eyes. Both of her eyes were congested with some petechia noted in her right eye. There was a red discoloration to the central portion of her left cheek and there was a red discoloration to the majority of her right cheek. Her upper lip, and the right side of her lower lip appeared to be dehydrated. There was a red horizontal discoloration along the right central, front central, and left central portion of her neck. There was a red discoloration to her outer upper right arm and there were 2 horizontal markings to the back central portion of her left arm. There were multiple horizontal and diagonal markings with abrasions to the central portion of her back. There was a yellow discoloration and a red discoloration to the front of her left shoulder and there was another yellow discoloration to the top of her left shoulder. There was an abrasion to the back of her right shoulder. There were abrasions to top central portion of her left forearm. There was a bruise to the front of her right hip, and there was another bruise to the front of her left hip. There was a bruise to her outer left knee and there was a bruise to the front of her right knee. There were ligature marks around both of her wrists, and both of her ankles. No defense wounds were noted to her hands. Rigor mortis was absent, and lividity was not observed.

Identification:

On Wednesday 09/13/2023 at 0819 hours, the Los Angeles County Regional Identification System positively identified the decedent as Maleesa Marie Mooney with a DOB of 10/16/1991 by her fingerprints through Livescan.

On Wednesday 09/13/2023 at 0821 hours, the Department of Justice confirmed the decedent's identification as Maleesa Mooney with the same DOB by her fingerprints through Livescan. On Wednesday 09/13/2023 at 0906 hours, the Federal Bureau of Investigations confirmed the decedent's identification as Maleesa Mooney with the same DOB by her fingerprints through Livescan. Per the decedent's California driver's license, her name is Maleesa Marie Mooney with a DOB of 10/16/1991.

Next of Kin Notification:

On Wednesday 09/13/2023 at an unknown time, Detectives Notified [REDACTED] the decedent's mother, of her daughter's death. When I spoke with [REDACTED], the decedent's Aunt, over the phone, she confirmed this information. She stated that the decedent does not have a will, she is not married, and she does not have any children.

Tissue Donation:

Due to the time lapse, the decedent is no longer a viable candidate for tissue and organ donation.

Autopsy Notification:

Both Detective Marsinek and Detective Pierce require a 2-hour notification prior to the examination. Please see case notes for their contact information.

Evidence:

Underwear + Pad collected on 2023-09-13, at approximately 06:07:00 hours - Criminalist - SEM - Ingalls, Samantha



LOS ANGELES COUNTY

Medical Examiner

Case Number: **2023-12242** - Decedent's Name: **MOONEY, MALEESA MARIE**

Cheetah print romp collected on 2023-09-13, at approximately 06:04:00 hours - Criminalist - SEM - Ingalls, Samantha
Ankle Ligature collected on 2023-09-13, at approximately 05:23:00 hours - Criminalist - SEM - Ingalls, Samantha
Black tank top collected on 2023-09-13, at approximately 05:17:00 hours - Criminalist - SEM - Ingalls, Samantha
Bracelet collected on 2023-09-13, at approximately 05:42:00 hours - Criminalist - SEM - Ingalls, Samantha
Fingernail Kit collected on 2023-09-13, at approximately 05:53:00 hours - Criminalist - SEM - Ingalls, Samantha
Gold top collected on 2023-09-13, at approximately 04:58:00 hours - Criminalist - SEM - Ingalls, Samantha
Hair Kit collected on 2023-09-13, at approximately 05:56:00 hours - Criminalist - SEM - Ingalls, Samantha
Hot pink mesh skirt collected on 2023-09-13, at approximately 05:40:00 hours - Criminalist - SEM - Ingalls, Samantha
Knotted Cheetah Dress collected on 2023-09-13, at approximately 05:00:00 hours - Criminalist - SEM - Ingalls, Samantha
Long sleeve gray shirt + hand towels x3 collected on 2023-09-13, at approximately 04:52:00 hours - Criminalist - SEM - Ingalls, Samantha
Pink Sleeveless Zippered Hoodie collected on 2023-09-13, at approximately 08:06:00 hours - Criminalist - SEM - Ingalls, Samantha
Pink Tank Shirt collected on 2023-09-13, at approximately 04:56:00 hours - Criminalist - SEM - Ingalls, Samantha
Sexual Assault Kit collected on 2023-09-13, at approximately 06:20:00 hours - Criminalist - SEM - Ingalls, Samantha
Wrist Ligature collected on 2023-09-13, at approximately 05:31:00 hours - Criminalist - SEM - Ingalls, Samantha

Investigator: McCracken, Kristy
Inv. Report Date/Time: 10/9/2023 at 21:54:00

Reviewed By: Yagerlener, Kelly
Reviewed Date/Time: 10/9/2023 at 23:34:00

SEXUAL ASSAULT EVIDENCE FORM

COUNTY OF LOS ANGELES

MEDICAL EXAMINER

81

Criminalist: S. Ingalls
 Forensic Science Laboratories
 Phone #: 323-343-0530

CC#: 2023-12242

Decedent: _____

Male Female

SEXUAL ASSAULT EVIDENCE COLLECTION STARTED: Location: FSC Date: 09.13.23 Time: 0611

SEXUAL ASSAULT EVIDENCE COLLECTION COMPLETED: Location: FSC Date: 09.13.23 Time: 0620

| Comments, if applicable | Time | Scene | FSC | INITIALS | Not Collected |
|---|------|-------|-----|----------|---------------|
| 1. ORAL CAVITY: Swab set <i>see note below</i> | | | | | ✓ |
| 2. NECK: Wet swab set | 0611 | | ✓ | SI | |
| 3. LEFT BREAST: Wet swab set | 0612 | | ✓ | SI | |
| 4. RIGHT BREAST: Wet swab set | 0613 | | ✓ | SI | |
| 5. INNER THIGHS: Wet swab set | 0614 | | ✓ | SI | |
| 6. EXTERNAL GENITAL: Wet swab set | 0615 | | ✓ | SI | |
| 7. VAGINAL CAVITY: Swab set | 0616 | | ✓ | SI | |
| 8. CERVICAL: Swab set | 0617 | | ✓ | SI | |
| 9. PENILE SHAFT: Wet swab set | NIA | | | | |
| 10. ANAL OPENING: Wet swab set | 0618 | | ✓ | SI | |
| 11. RECTAL: Swab set | 0619 | | ✓ | SI | |
| 12. PUBIC HAIR COMBING <i>shaved</i> | | | | | ✓ |
| 13. OTHER EVIDENCE packaged with the sexual assault evidence: | | | | | |
| ▪ | | | | | |
| ▪ | | | | | |

14. ALTERNATE LIGHT SOURCE (check applicable light source used below)

- Foster + Freeman Crime Lite 2 (blue light fixed at 420 nm - 470 nm)
 Foster + Freeman Crime Lite 42S (UV light fixed at 350 nm - 380 nm)

| Area of Body | Goggle Color | Findings/Comments | Time | Scene | FSC | INITIALS | Not Assessed |
|--------------|---------------|---------------------------|------|-------|-----|----------|--------------|
| Anterior | <i>orange</i> | <i>nothing remarkable</i> | 0610 | | ✓ | SI | |
| Posterior | <i>orange</i> | <i>" "</i> | 0620 | | ✓ | SI | |

COMMENTS: Each swab set has been air dried, packaged into a cardboard box, and stored at room temperature while in the custody of the Department of Medical Examiner-Coroner.

- pink clothing in mouth
- maxi pad w/ apparent blood & fecal matter collected w/ underwear
- female dec'd bound (hands, wrists, neck); found in refrigerator

Criminalist Signature/Date: S. Ingalls 09.13.23